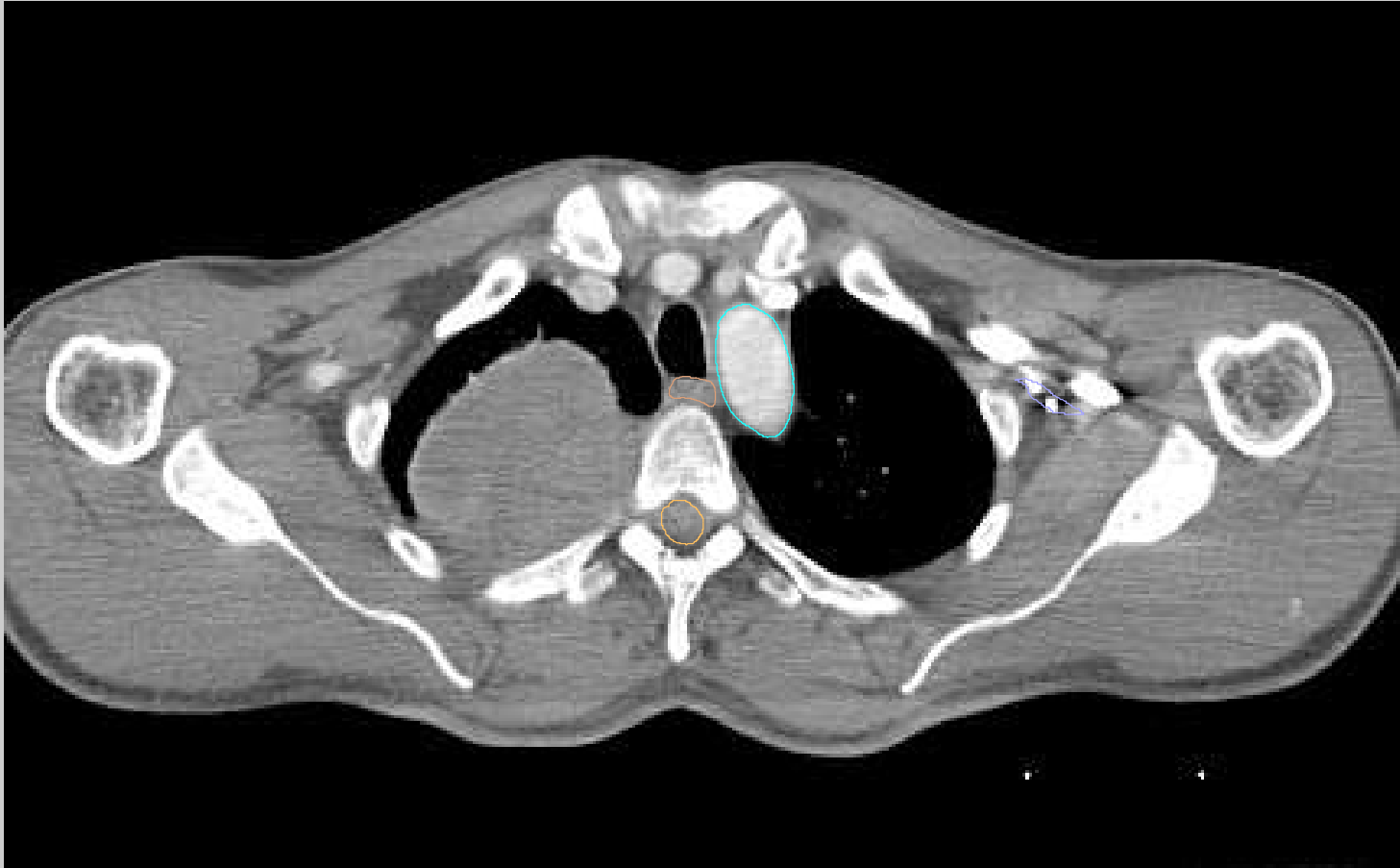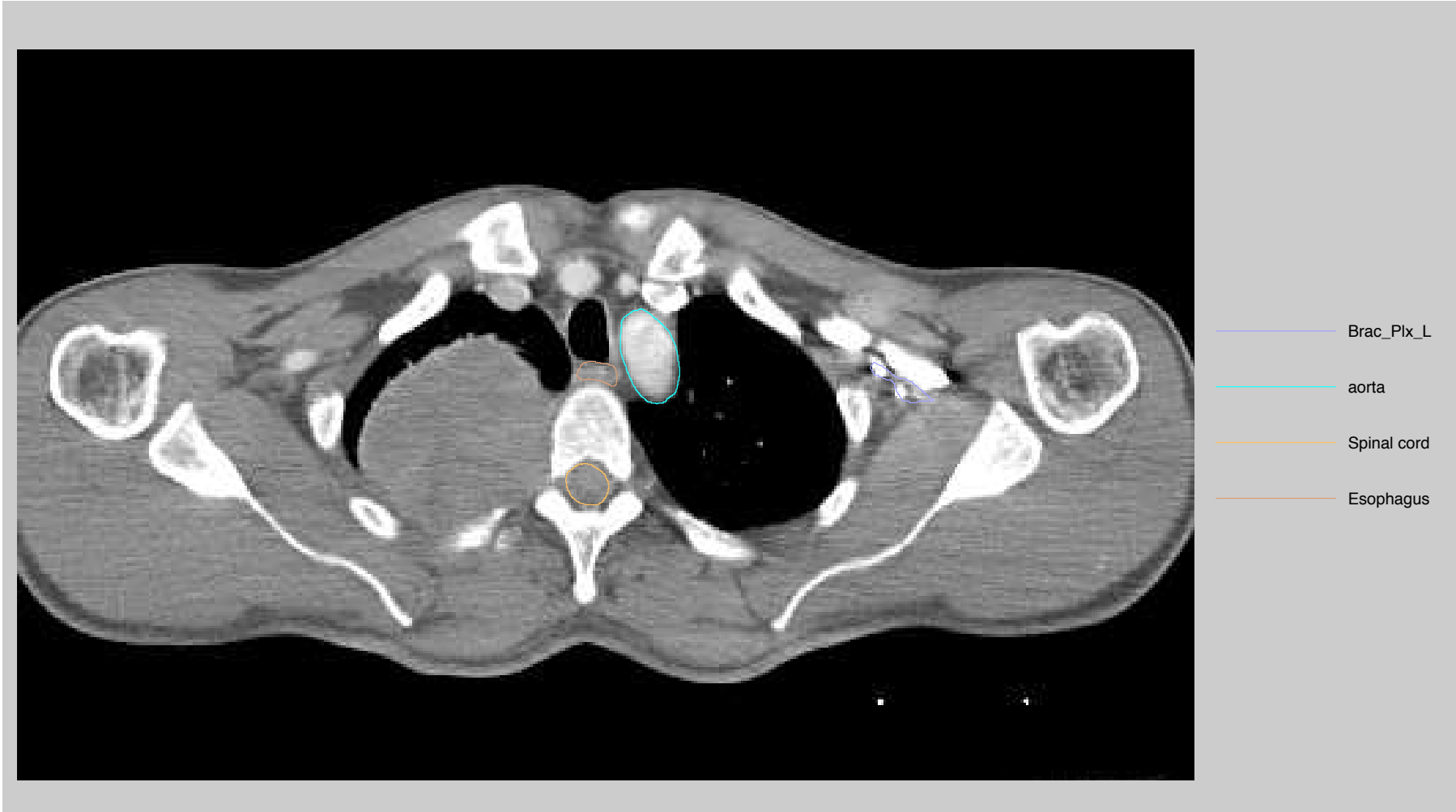

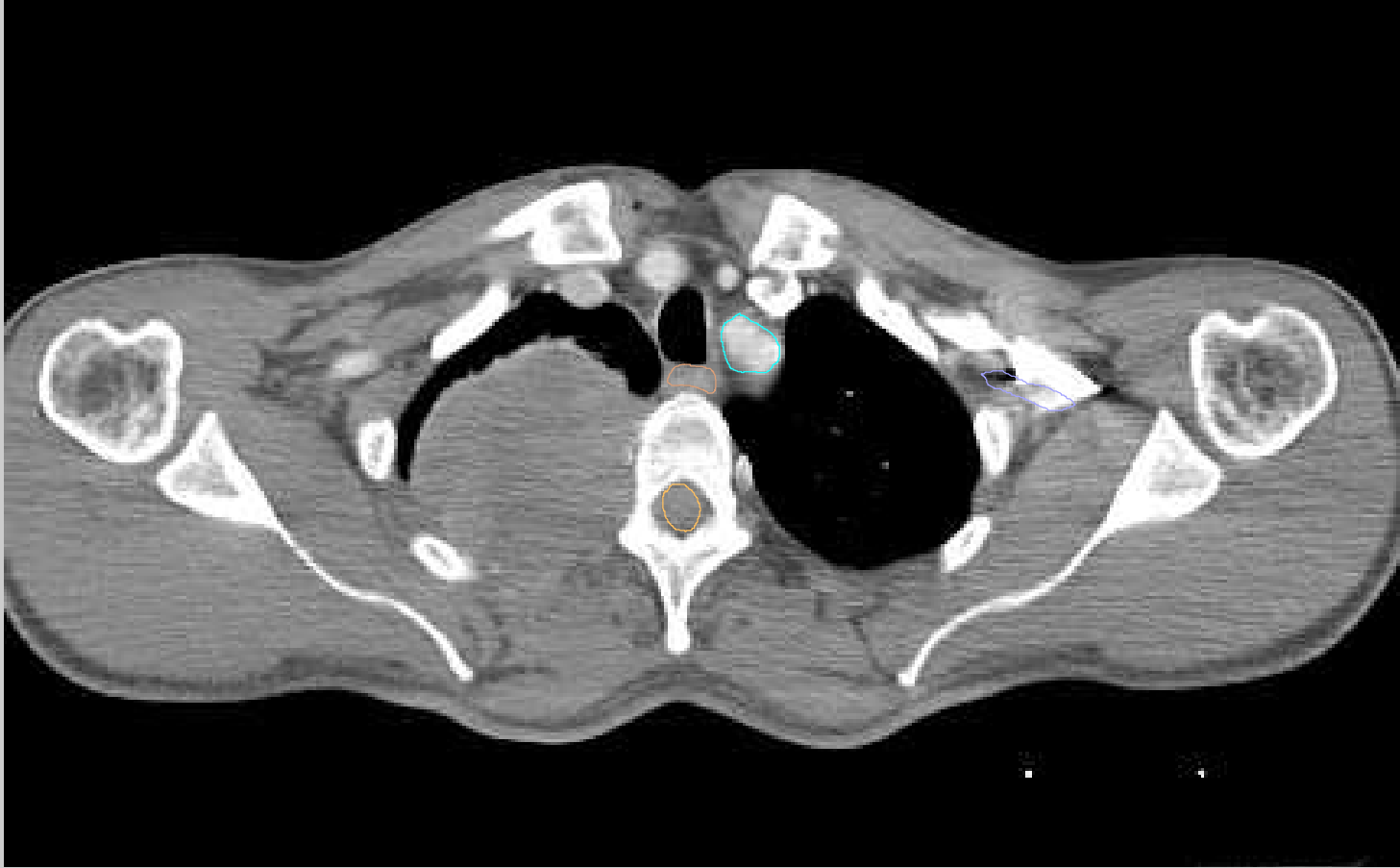
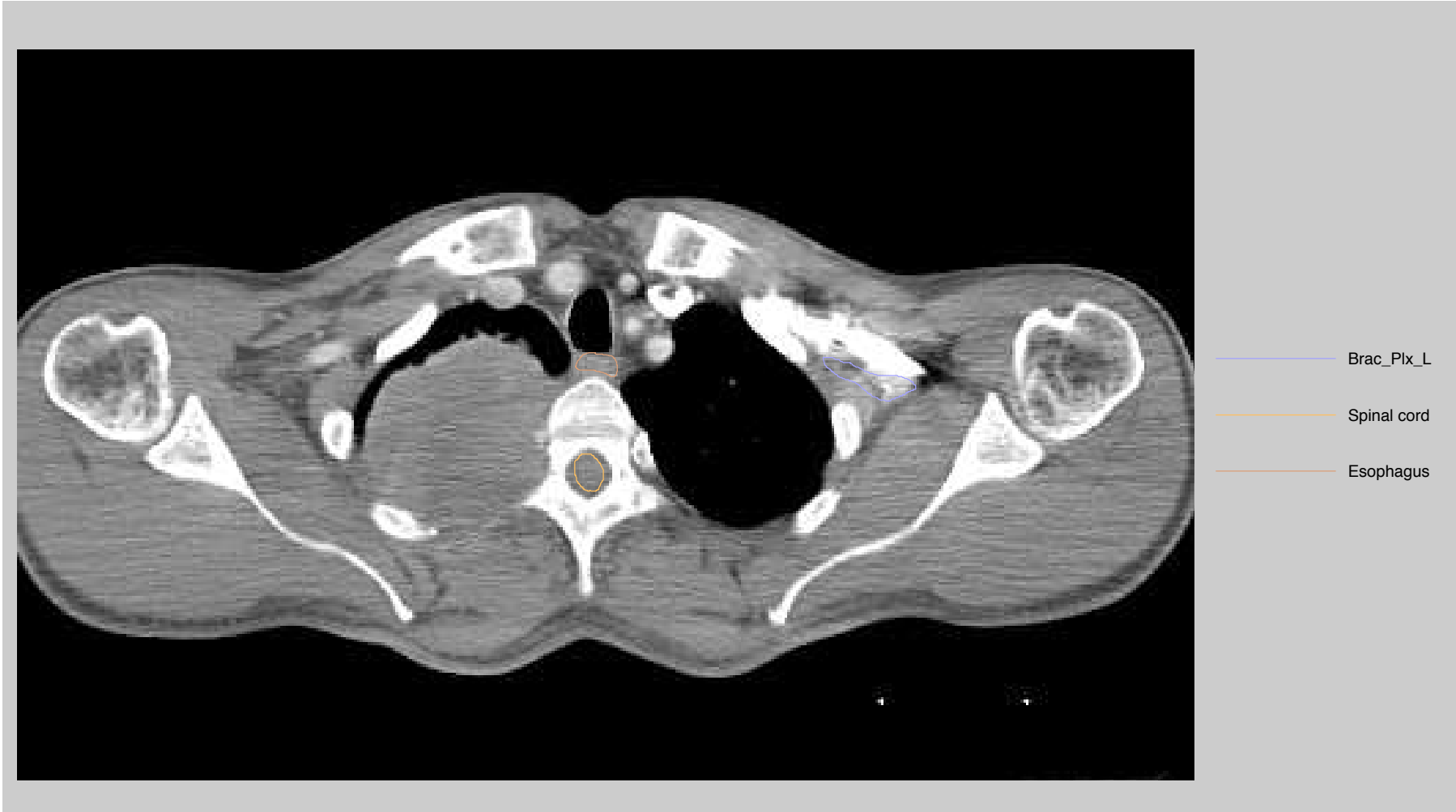


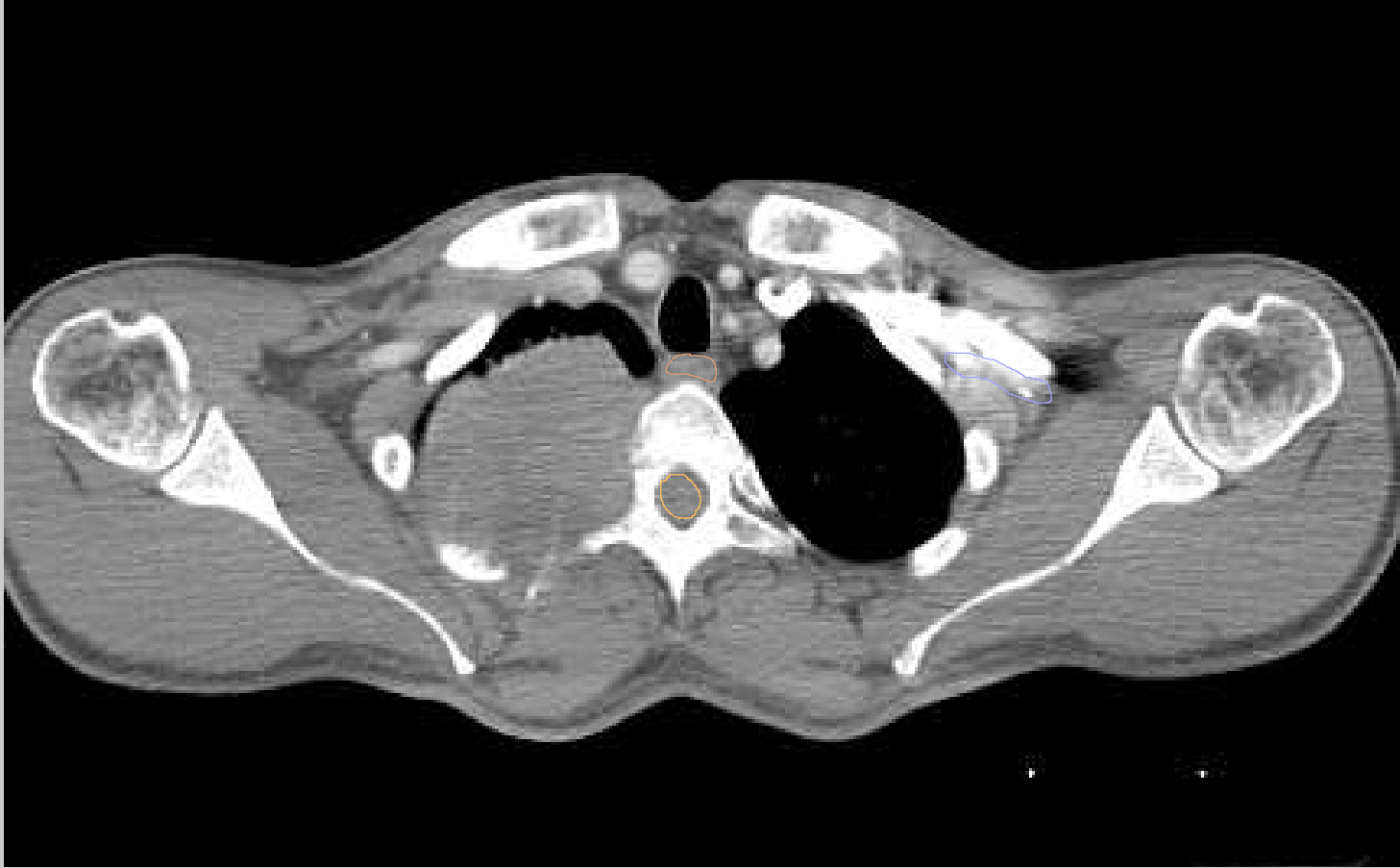
- Brac\_Plx\_L
- aorta
- Spinal cord
- Esophagus



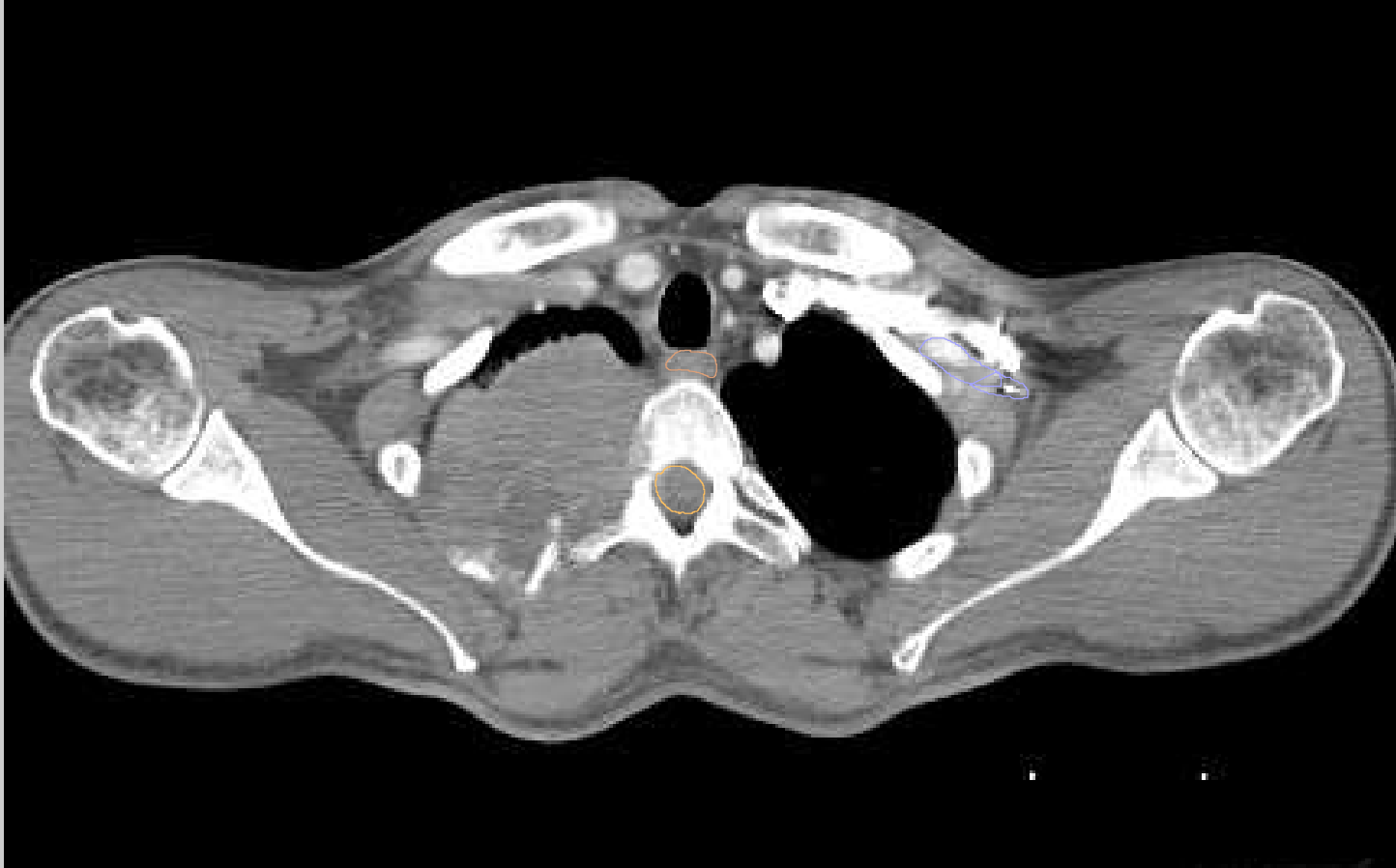


- Brac\_Plx\_L
- aorta
- Spinal cord
- Esophagus

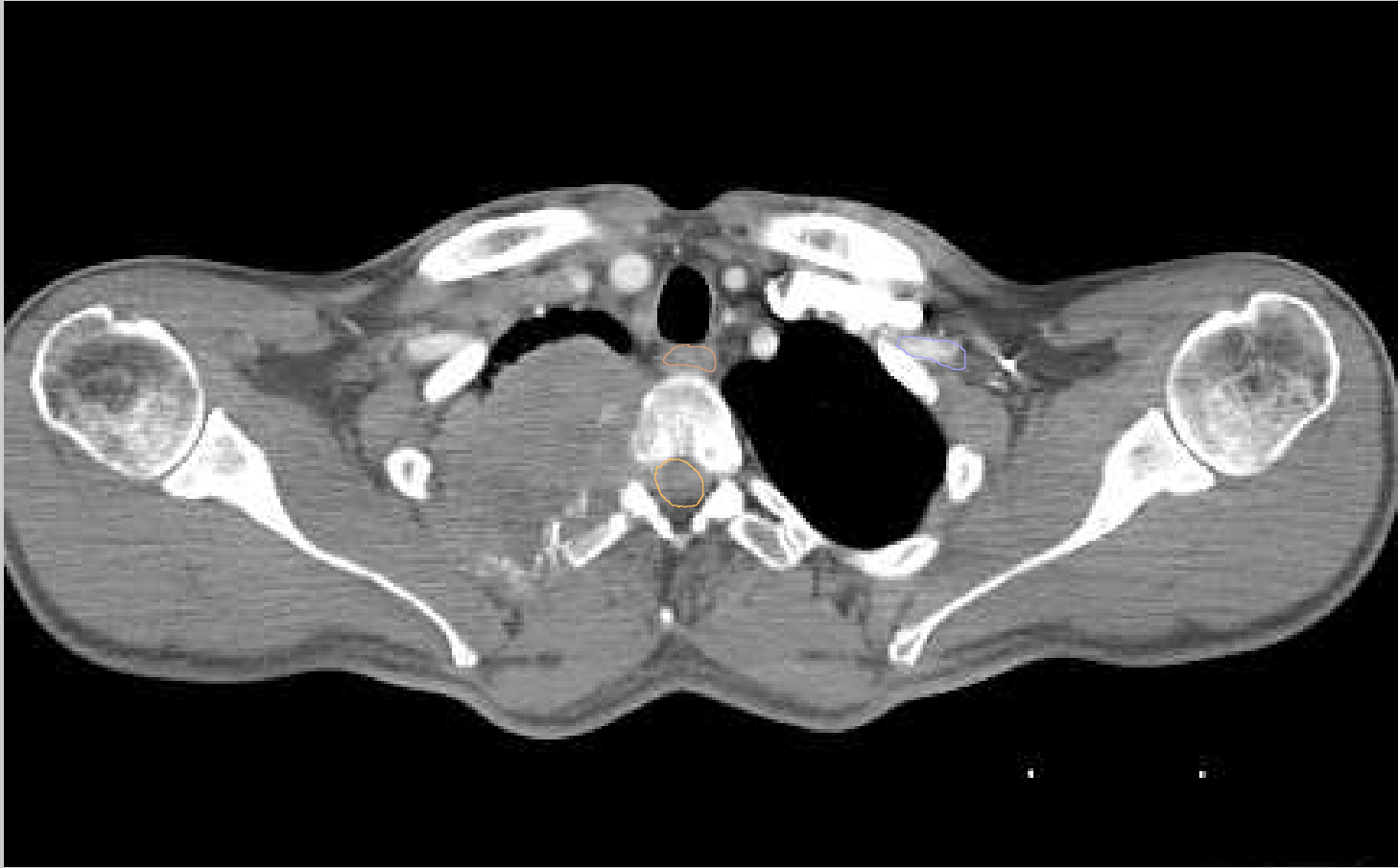



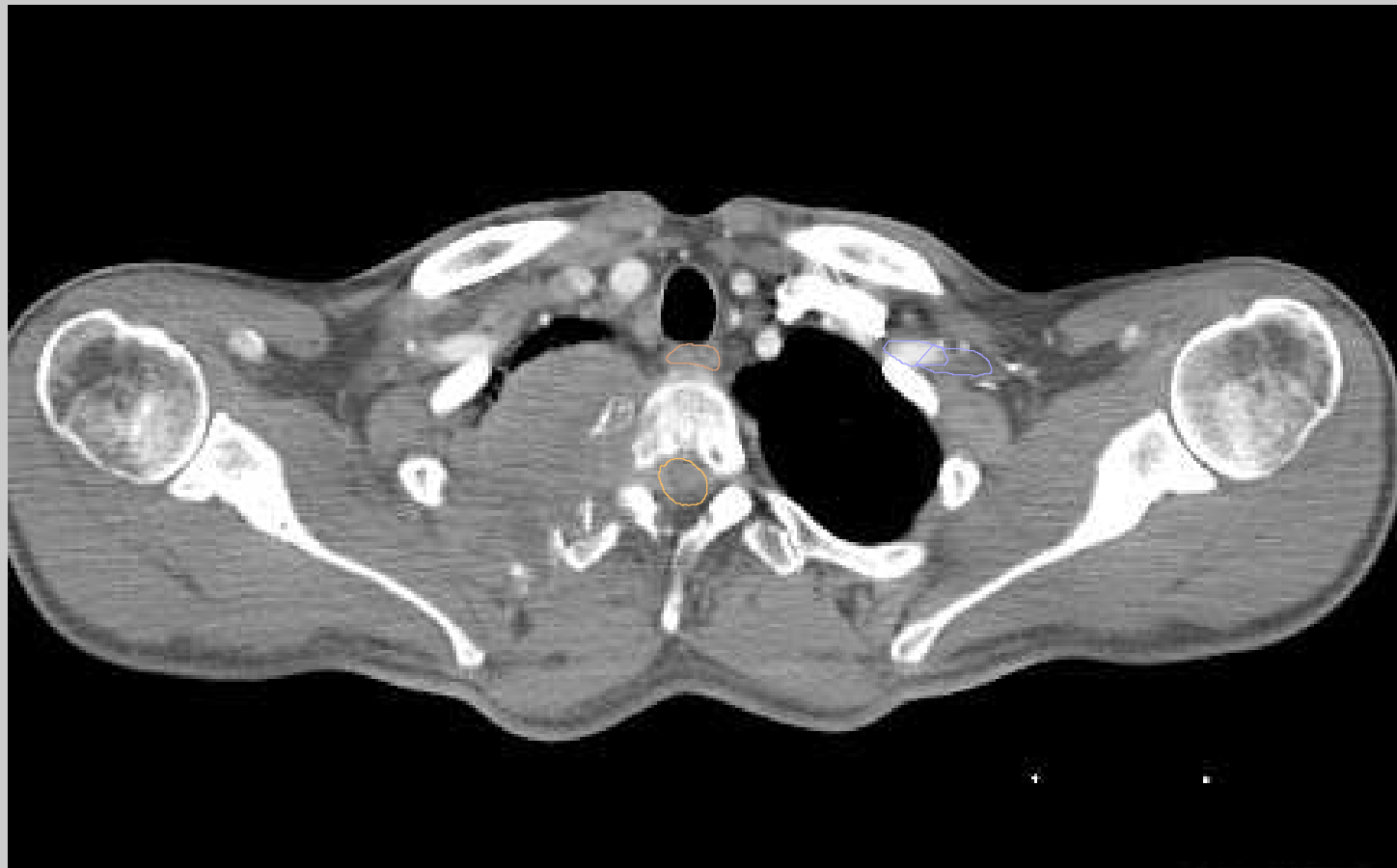
- Brac\_Plx\_L
- Spinal cord
- Esophagus



- Brac\_Plx\_L
- Esophagus
- Spinal cord

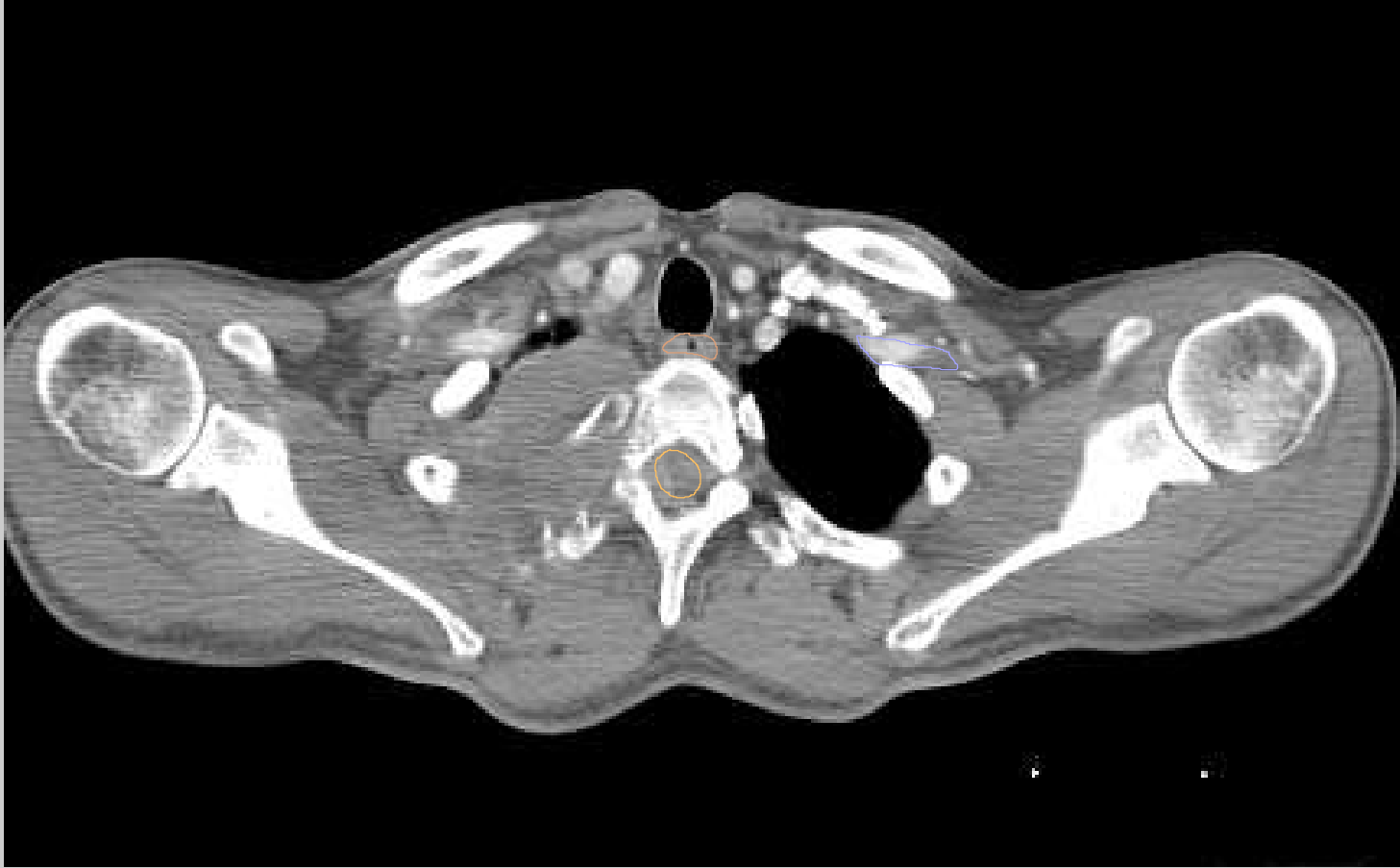


- Brac\_Plx\_L
- Spinal cord
- Esophagus

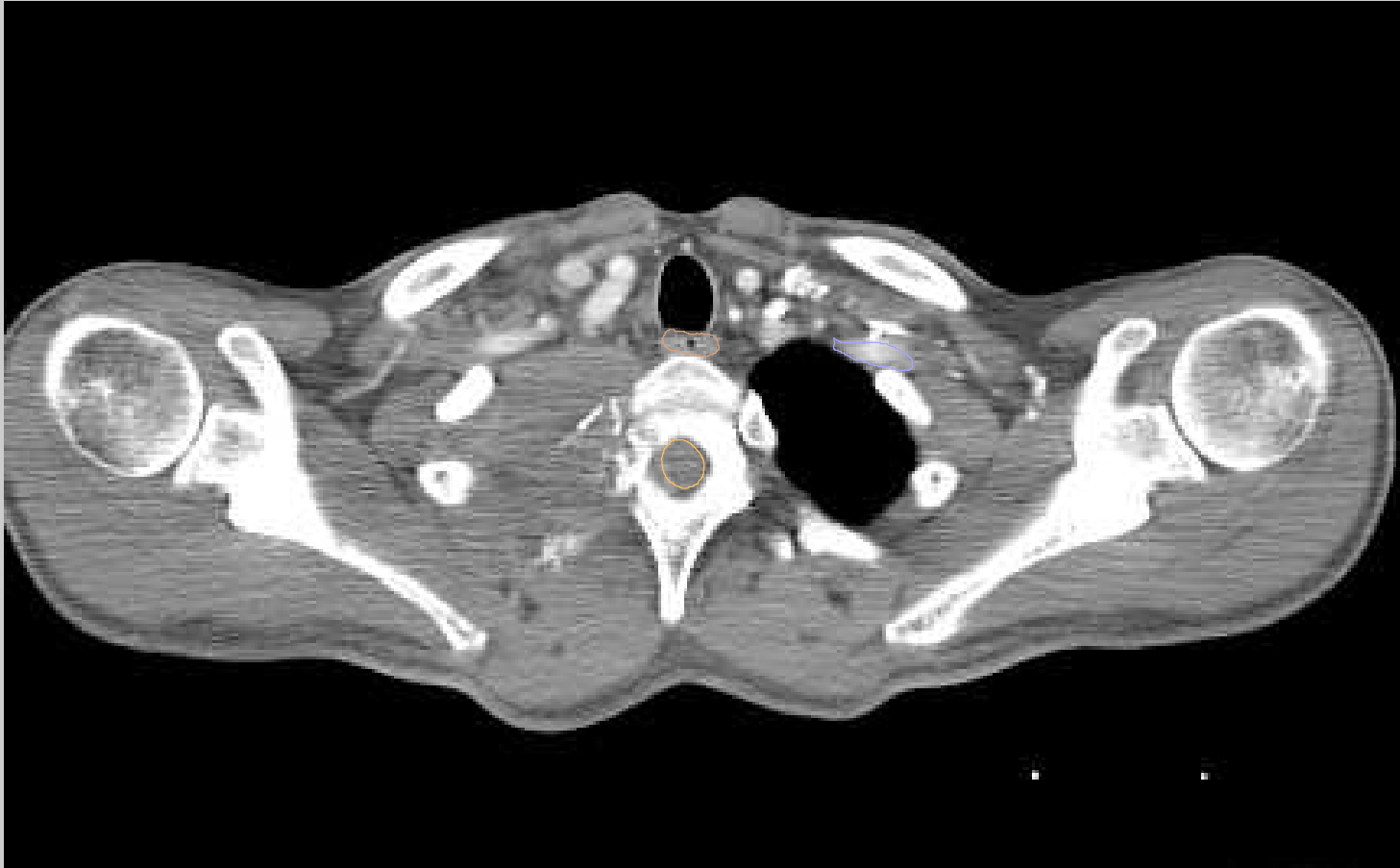


- Brac\_Plx\_L
- Esophagus
- Spinal cord

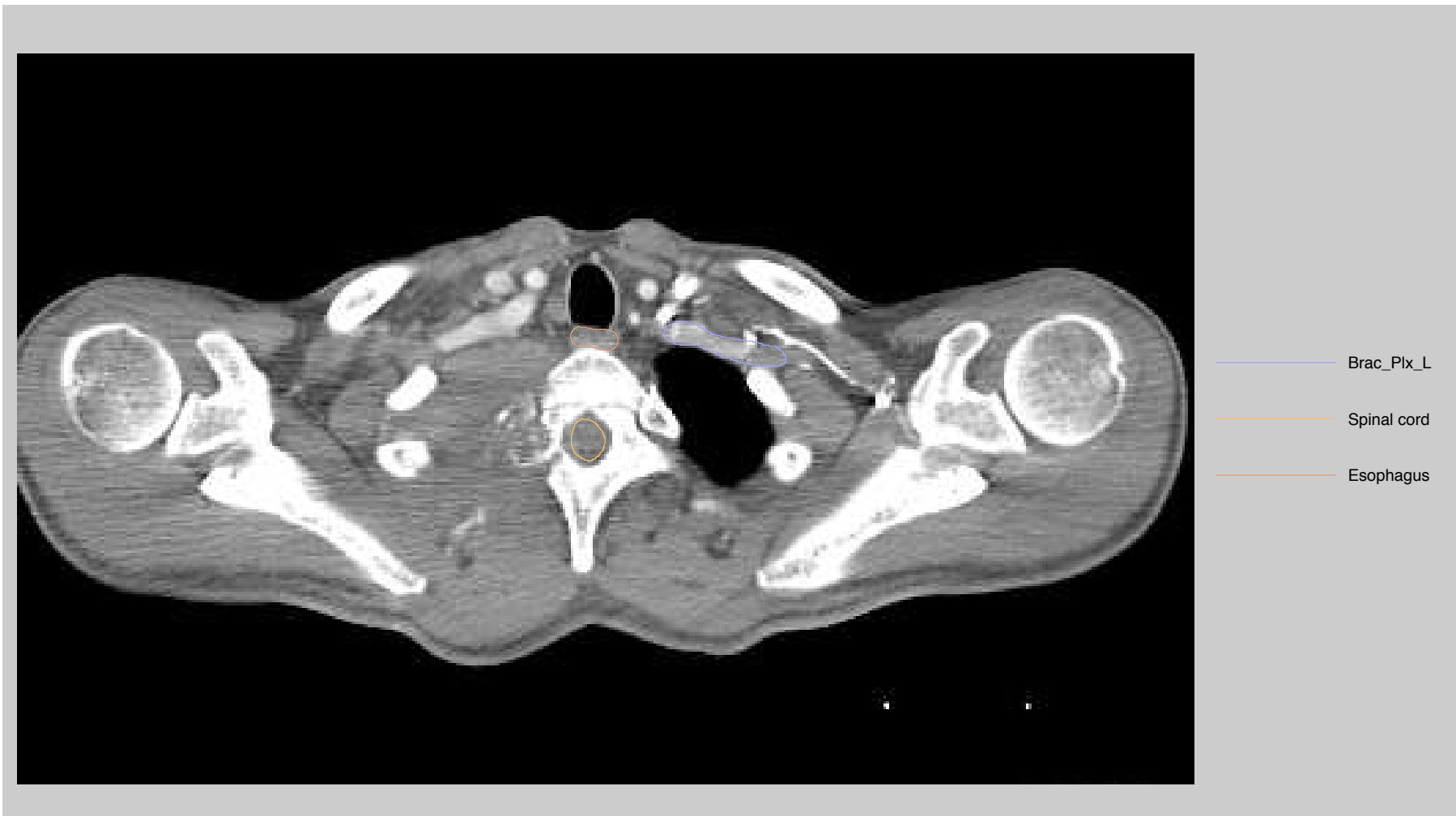

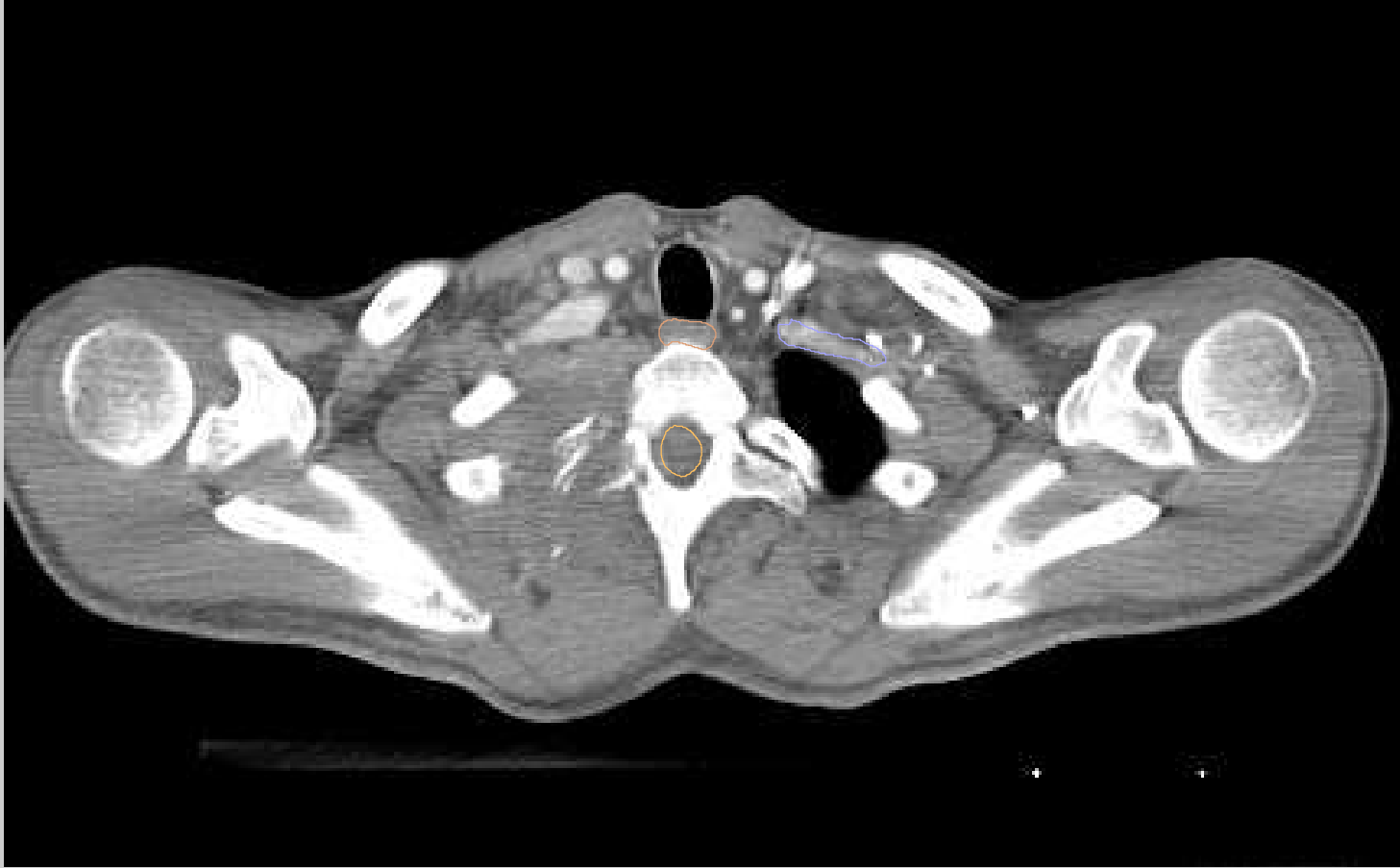


- Brac\_Plx\_L
- Spinal cord
- Esophagus

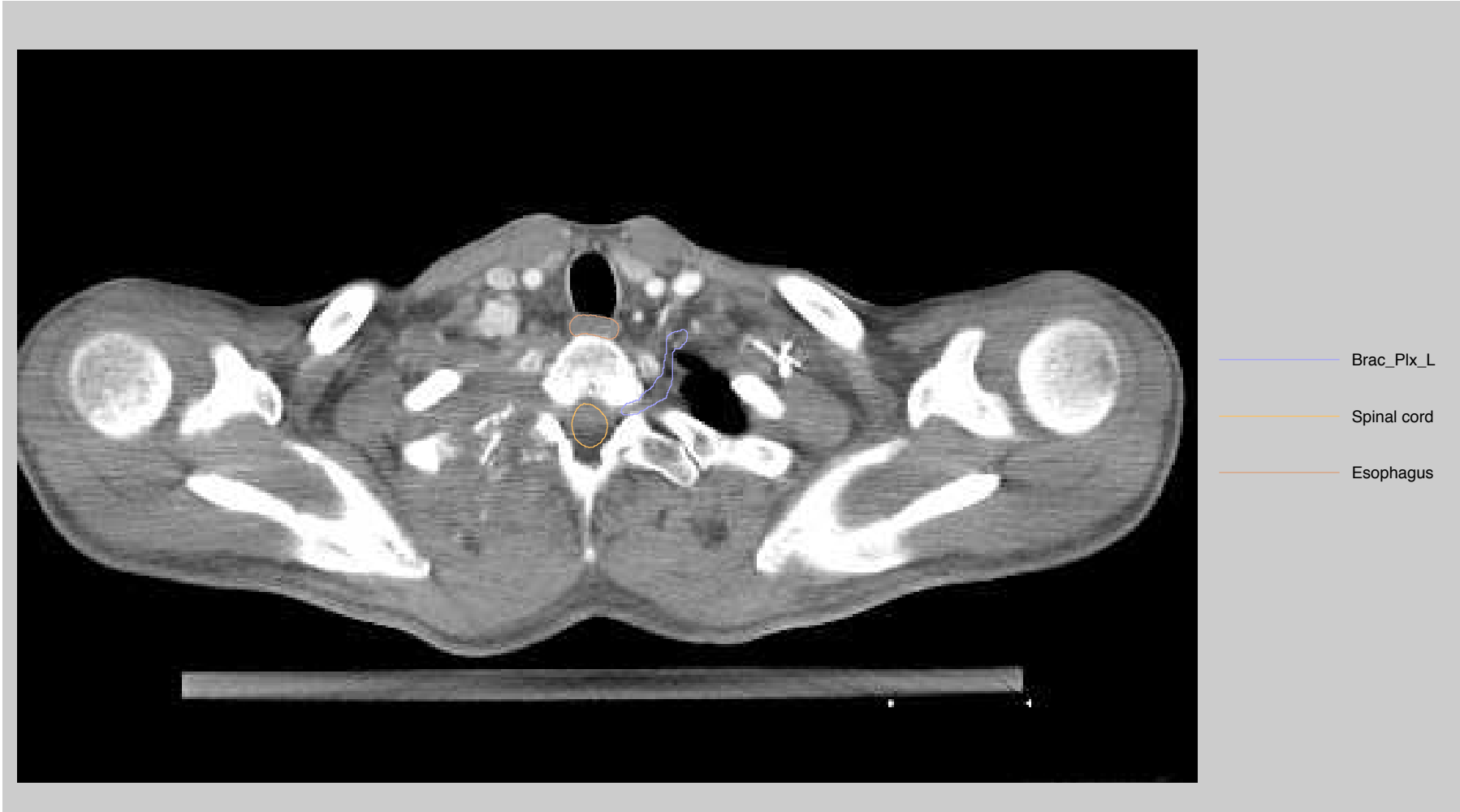


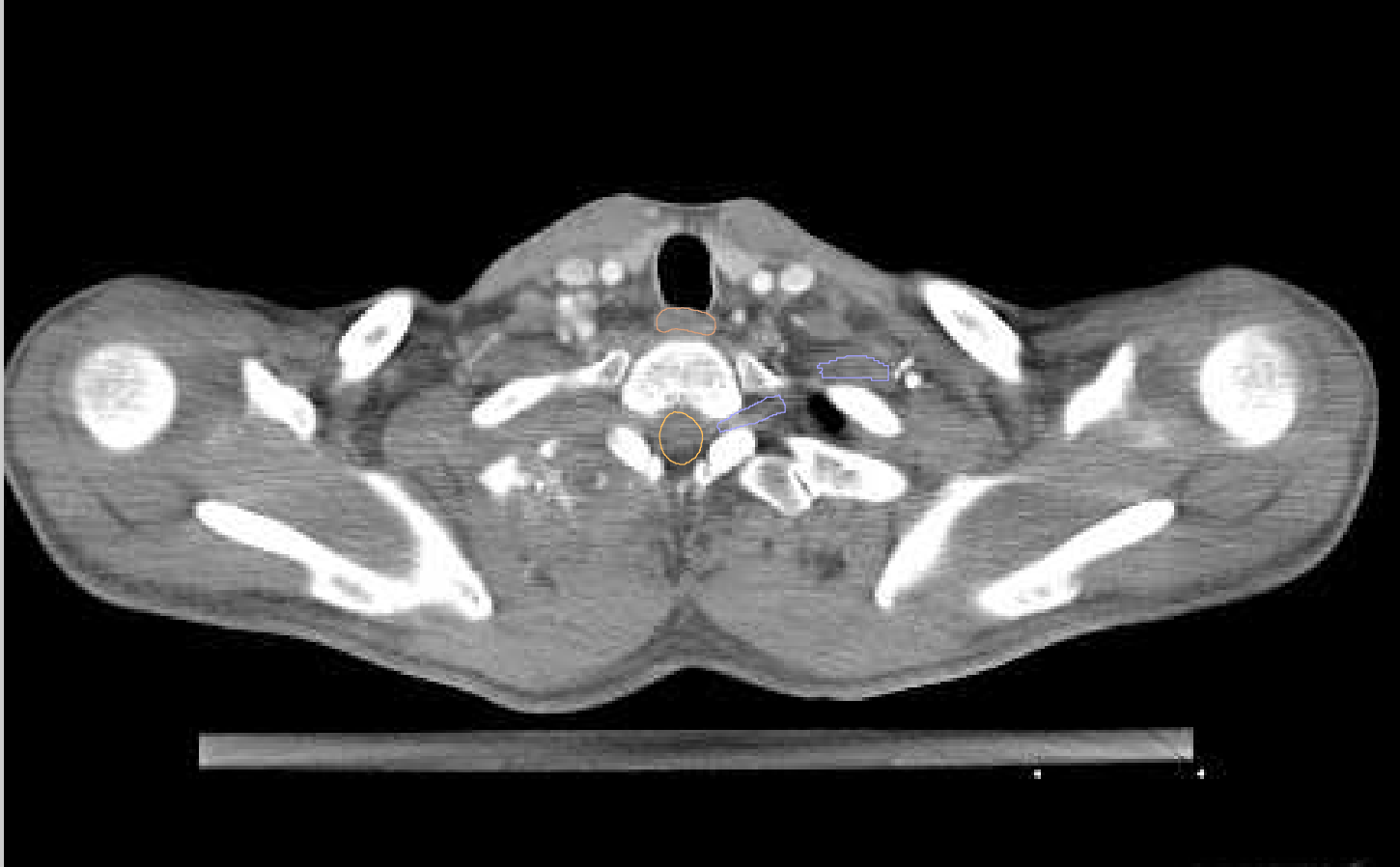
- Brac\_Plx\_L
- Spinal cord
- Esophagus



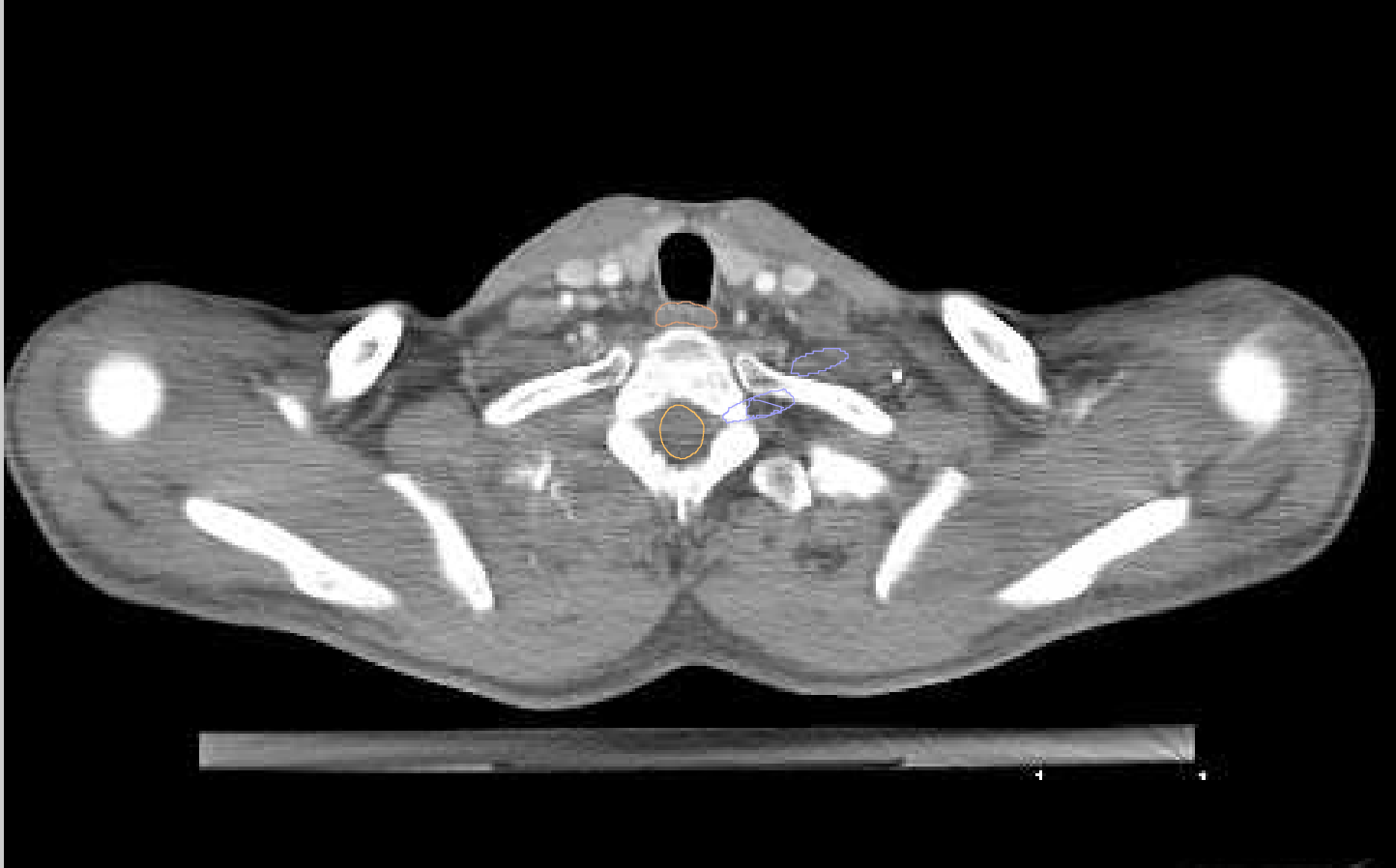


- Brac\_Plx\_L
- Spinal cord
- Esophagus

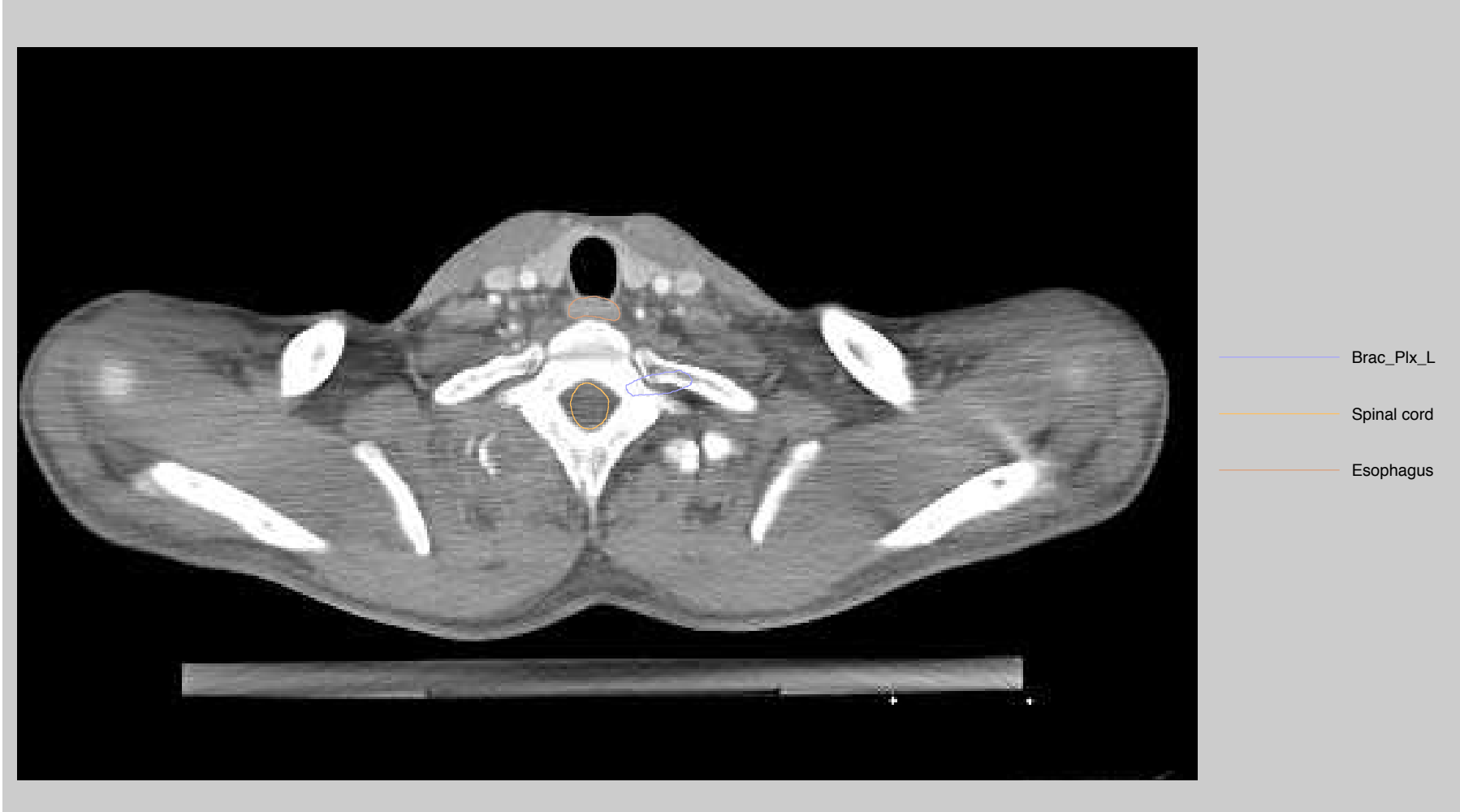




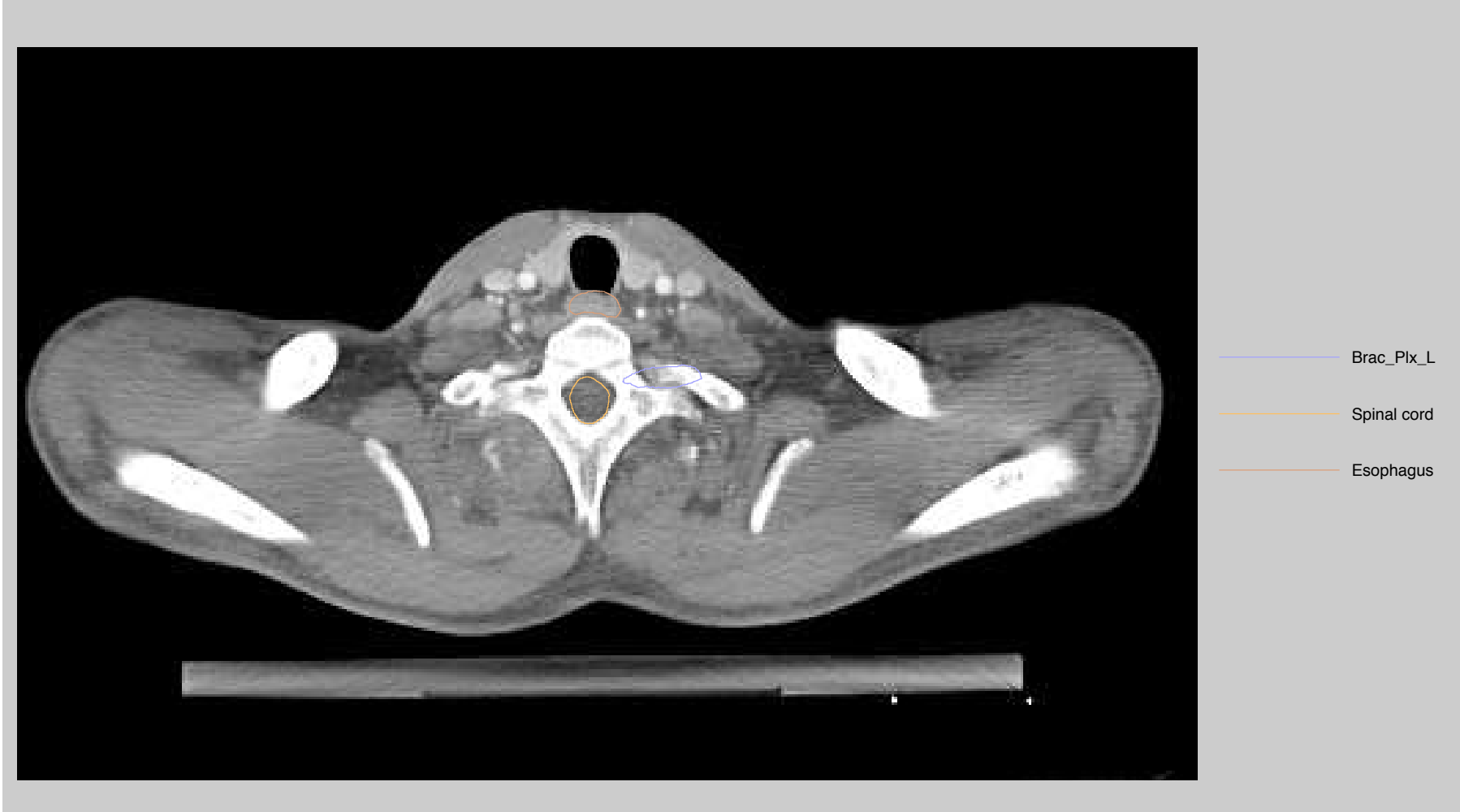- Brac\_Plx\_L
- Esophagus
- Spinal cord

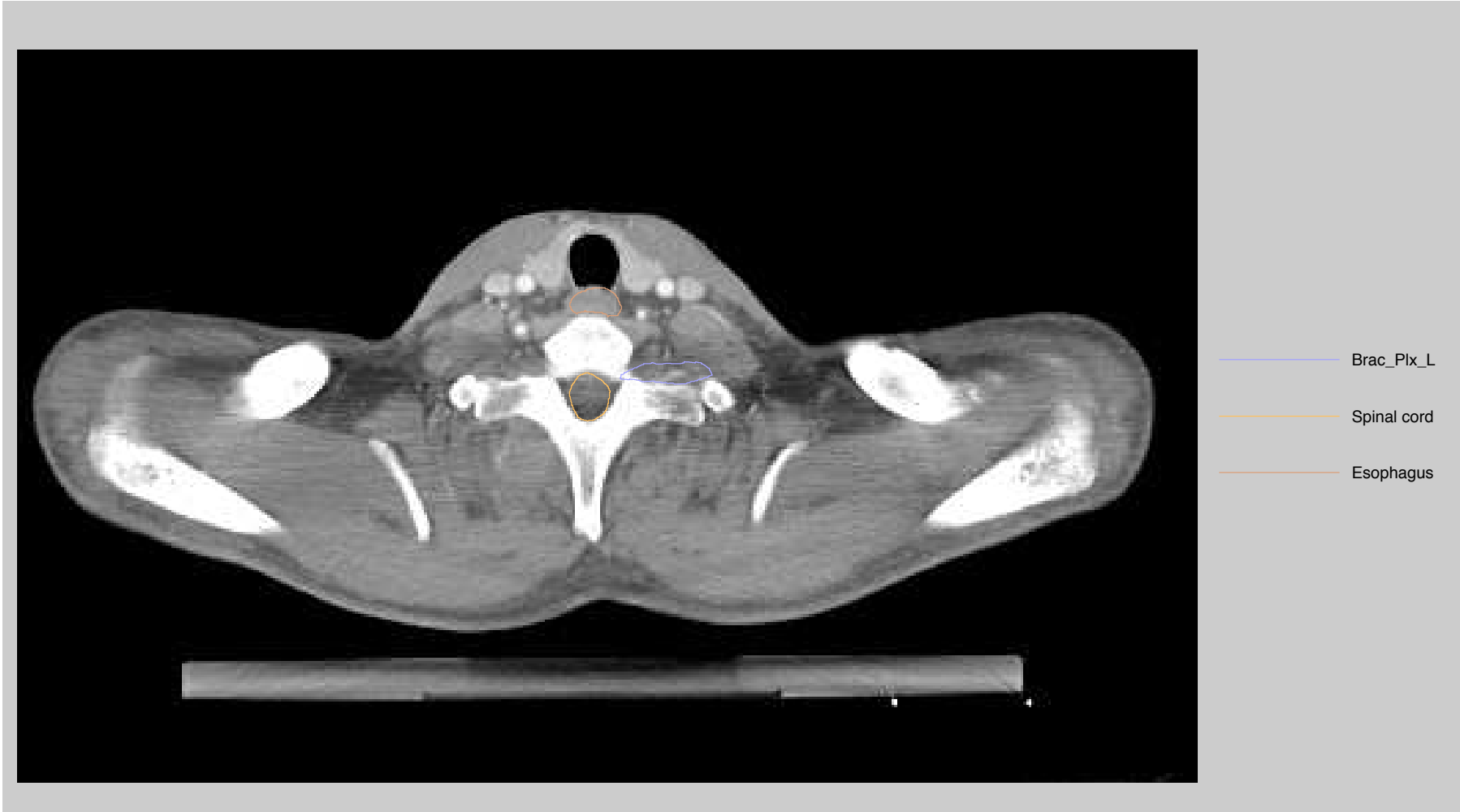

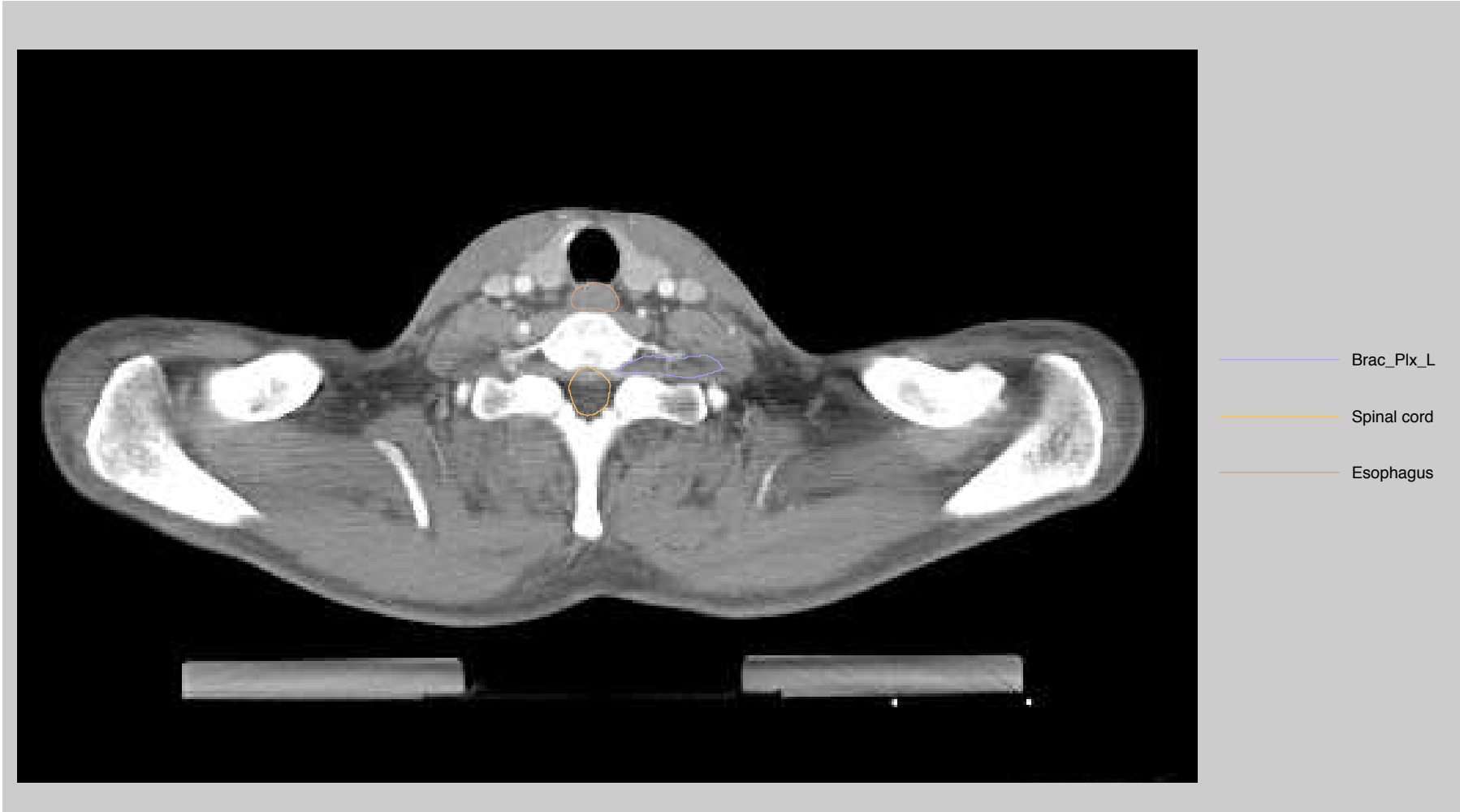
- Brac\_Plx\_L
- Esophagus
- Spinal cord

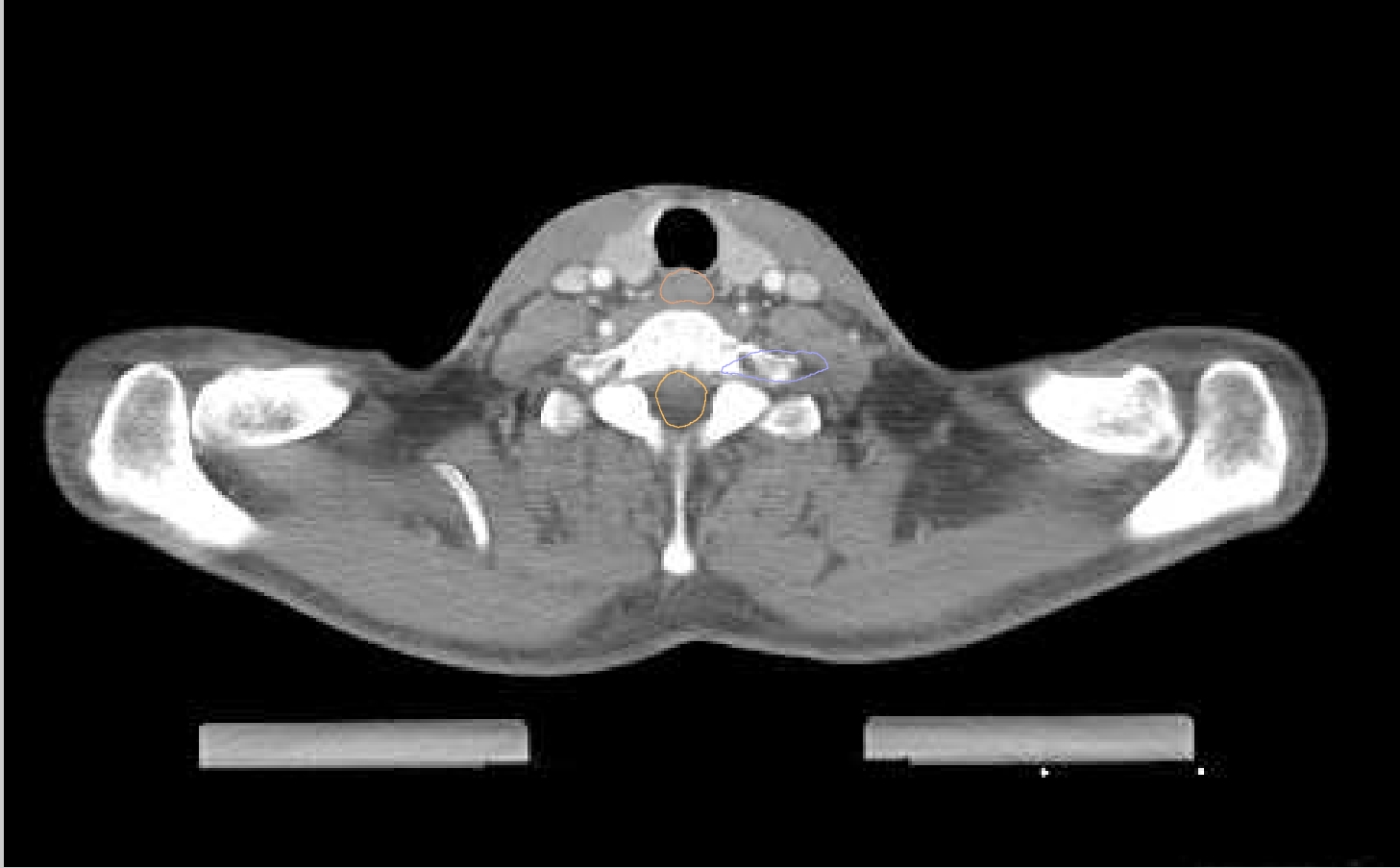











- Brac\_Plx\_L
- Spinal cord
- Esophagus

